

# Condylar Fracture: Nontreatment Case Followed Over 23 Years

German Omar Ramirez-Yañez, DDS, MDSc<sup>1</sup>/Phillip James Saxby, MDSc<sup>2</sup>/  
William George Young, BDS, MSc, PhD, FFOP(RACP)<sup>3</sup>

*This article describes a case of early mandibular condylar fracture in a female patient. Follow-up visits over about 23 years without treatment showed completely re-stabilized anatomy and function after the pubertal growth spurt. Temporary ankylosis and lack of growth with severe deviation and facial asymmetry had been initially observed. The management philosophy of pediatric condylar fractures is discussed and a conservative approach is suggested for such cases. World J Orthod 2002;3:349–352.*

Condylar fractures make up 20% to 40% of mandibular fractures.<sup>1,2</sup> Various treatments have been advocated for the management of this problem, including intraoral fixation,<sup>3,4</sup> functional appliances,<sup>5–7</sup> physiotherapy,<sup>5</sup> surgical treatment including relocation of the dislocated condyle,<sup>8</sup> and direct fixation of the fragments.<sup>4,8,9</sup> Authors leaning toward surgical approaches report faster recovery through restoration of the anatomy,<sup>9</sup> while conservative approaches seem to result in adaptation.<sup>5</sup> Ultimately, however, no differences in function have been demonstrated between surgical and nonsurgical treatments.<sup>10</sup> Notably, the quality of healing seems to be better when the fracture occurs at an early age.<sup>11,12</sup>

This article discusses a patient in whom a fracture occurred in early infancy, at approximately 10 months of age. The fracture was diagnosed 7 years later. Over a 23-year period after diagnosis, the frac-

tured condyle had totally remodeled. Function was with some malocclusion, but the remodeling occurred without any treatment, since the patient refused it.

## CASE REPORT

The patient was initially referred to the School of Dentistry at the University of Queensland by her dentist, who was concerned about facial abnormalities. The patient was a healthy girl of 7 years 10 months of age, with no remarkable medical history. At about 10 months of age, she had fallen from some steps. On clinical examination, the patient had an underdeveloped jaw on the left side, with maximum opening of 3.5 cm and lateral deviation to the left (Fig 1a). In occlusion, there was a 1-cm deviation of the mandibular incisors from the midline. During palpation, the left condyle only rotated in the fossa and did not come forward. The right condyle rotated and came forward. The orthopantomogram (OPG) showed a left mandibular corpus and ramus shorter than the right (approximately 0.5 and 1 cm, respectively). The head of the left condyle was tilted vertically and slightly anteriorly, instead of obliquely and posteriorly. It displaced further on the left side when both sides were measured from the auditory canal (Fig 1b). All of these observations were confirmed by tomography.

At this time, a diagnosis was made of left condylar hypoplasia and extra-articular ankylosis, probably caused by a condylar fracture during infancy. An

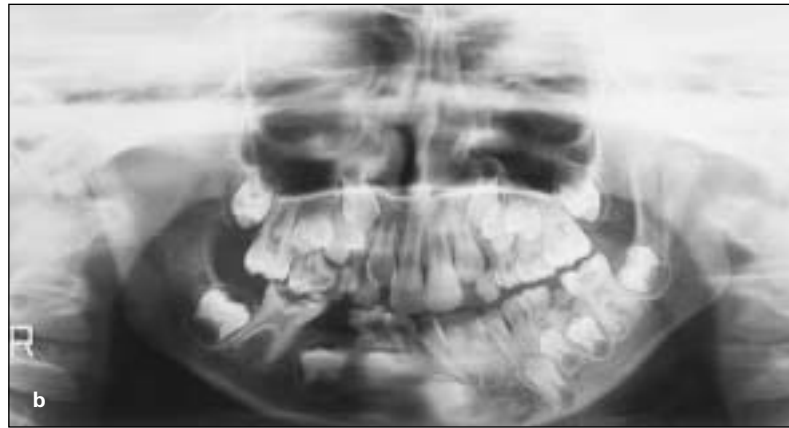
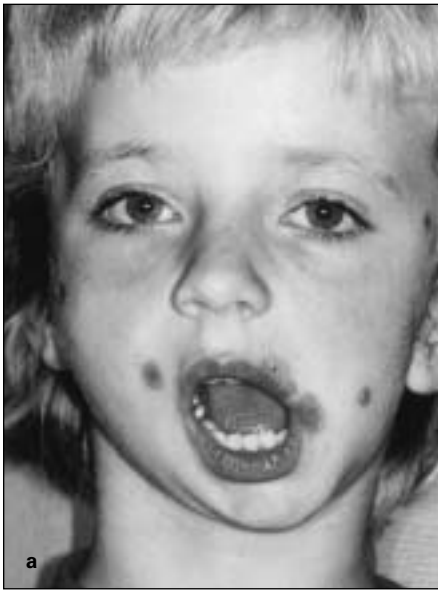<sup>1</sup>Doctoral Student, Department of Oral Biology and Pathology, School of Dentistry, The University of Queensland, Queensland, Australia.

<sup>2</sup>Private Practice of Orthodontics, West Bundaberg, Queensland, Australia.

<sup>3</sup>Professor, Department of Oral Biology and Pathology, School of Dentistry, The University of Queensland, Queensland, Australia.

### REPRINT REQUESTS/CORRESPONDENCE

Dr German O. Ramirez-Yañez, Department of Oral Biology and Pathology, School of Dentistry, The University of Queensland, St. Lucia, QLD 4072, Australia. E-mail: germanramirez@hotmail.com



**Fig 1** Patient at 7 years of age. **(a)** At maximal opening, showing a marked deviation to the left side. The facial crusted erythematous lesions are impetigo. **(b)** OPG showing an altered morphology of the mandibular condyle on the left side.

interdisciplinary approach with an orthodontist and a maxillofacial surgeon was recommended. The patient's parents decided not to follow these recommendations. Carious teeth were restored and follow-up radiographs were taken 2 years later. Some reduction in the facial asymmetry was observed clinically, but the OPG showed a situation similar to that previously observed (Fig 2).

Thirteen years later, the patient was contacted again and new records were taken. Clinical examination indicated that the deviation on opening had greatly improved (Fig 3a), as had her facial asymmetry. Palpation of the temporomandibular joints during opening revealed essentially normal movements on both sides. Her jaws functioned satisfactorily during this time, and her only concern was occasional clicking in her right joint. She had not received surgical nor orthodontic treatment over this period; even her obviously crowded occlusion was not of sufficient concern for her to have corrective orthodontic treatment. When the OPG was analyzed, the radiograph showed a totally remodeled condyle on the left side, with normal anatomy and correct positioning in the glenoid fossa (Fig 3b). A difference in size between both condyles was observed, with the right condyle almost 1 cm shorter and 0.5 cm thinner than the left condyle.

The patient was contacted again, 8 years later, and new records were taken. The deviation to the left side in maximal opening had disappeared (Fig 4a). The OPG showed a normal anatomy on the left side. A thinner condyle on the right side, to that

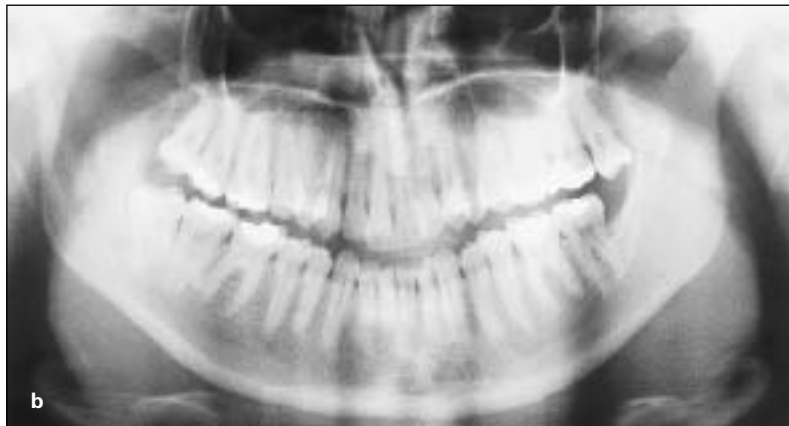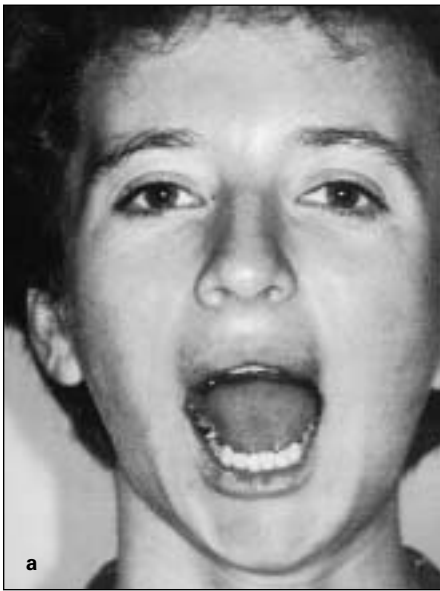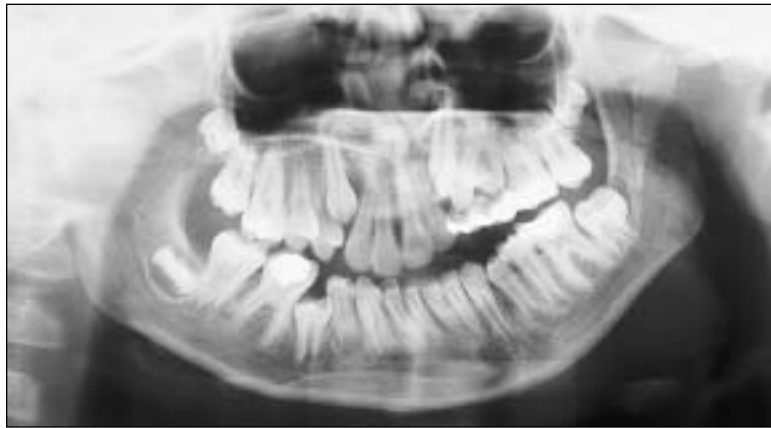observed in the previous OPG (see Fig 3b), was noted in the new OPG, as was an apparent reduction in its size (Fig 4b). However, the patient said her jaws functioned without problem; clicking in her right joint was still present.

## DISCUSSION

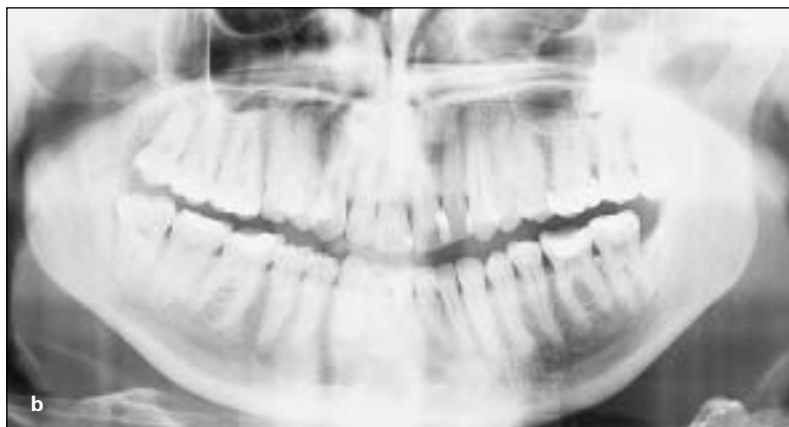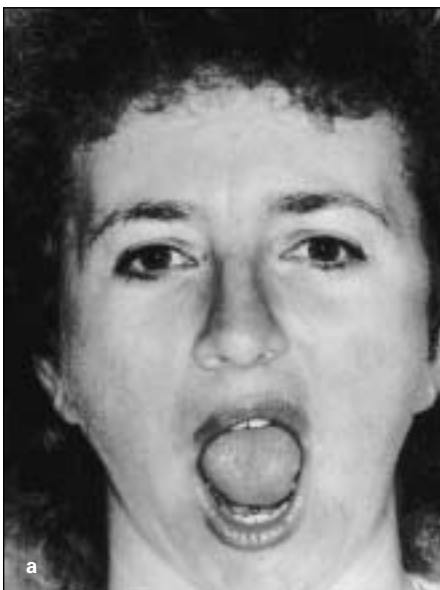Remodeling of condylar fractures appears to be a restitutive process in children.<sup>12</sup> However, anatomic and functional restitution is better when the fracture occurs at an early age.<sup>11</sup> Some radiologic aberrations have been reported as consequences of pediatric condylar fractures,<sup>13</sup> but normal function and favorable remodeling seem to occur in most cases of condylar fracture.<sup>14,15</sup> These responses seem to be age dependent.<sup>16,17</sup> Thus, this case supports the concept that condylar remodeling will occur in the majority of cases when the condylar fracture occurs during infancy. Although ankylosis and lack of normal growth seem to have occurred, total recovery was finally reached, not in early childhood but probably after the pubertal growth spurt.

Of central importance to the establishment of occlusion in such cases is the conservation of the normal relationship between the first permanent molars in the mixed dentition. This patient had several carious lesions in the deciduous and first permanent teeth. If the permanent molars were lost through caries, the outcome might have been less favorable.

**Fig 2** Patient at 9 years of age. OPG shows a situation similar to that shown in Fig 1b. Note the carious first mandibular molars have been restored.



**Fig 3** Patient at 22 years of age. **(a)** At maximal opening, showing a slight deviation to the left side. **(b)** OPG showing normal anatomy of the condyle on the left side. The condyle on the right side is observed to be of reduced size.



**Fig 4** Patient at 31 years of age. **(a)** The patient has maximal opening; no deviation is apparent. **(b)** OPG showing normal anatomy of the condyle on the left side, with an increased reduction in size of the condyle on the right side.

COPYRIGHT © 2002 BY QUINTESSENCE PUBLISHING CO, INC. PRINTING OF THIS DOCUMENT IS RESTRICTED TO PERSONAL USE ONLY. NO PART OF THIS ARTICLE MAY BE REPRODUCED OR TRANSMITTED IN ANY FORM WITHOUT WRITTEN PERMISSION FROM THE PUBLISHER.

## CONCLUSION

This case, with a follow-up period of 23 years without surgical or orthodontic treatment after the condylar fracture was diagnosed, suggests that the philosophy for treatment of condylar fractures should emphasize conservative methods, including functional appliances (which enhance metabolism and provide guidance to a more normal jaw relationship) or even no treatment. Caries control should be instituted to avoid premature loss of teeth, and following of facial growth and temporomandibular joint function should be maintained. Bilateral function may be important to avoid asymmetry in condylar size, as was observed in this case.

## REFERENCES

- Cascone P, Sassano P, Spallaccia F, Rivarolli A, Di-Paolo C. Condylar fractures during growth: Follow-up of 16 patients. *J Craniofac Surg* 1999;10:87-92.
- Lund K. Mandibular growth and remodelling processes after condylar fracture. A longitudinal roentgencephalometric study. *Acta Odontol Scand* 1974;33:3-117.
- Hovinga J, Boering G, Stegenga B. Long-term results of non-surgical management of condylar fractures in children. *Int J Oral Maxillofac Surg* 1999;28:429-440.
- Iizuka T, Lindqvist C, Hallikainen D, Mikkonen P, Paukku P. Severe bone resorption and osteoarthritis after miniplate fixation of high condylar fractures. A clinical and radiologic study of thirteen patients. *Oral Surg Oral Med Oral Pathol* 1991;72:400-407.
- Defabianis P. Condylar fractures treatment in children and youths: Influence on function and face development (a five-year retrospective analysis). *Funct Orthod* 2001;18:24-31.
- Strobl H, Emshoff R, Rothler G. Conservative treatment of unilateral condylar fractures in children: A long-term clinical and radiological follow-up of 55 patients. *Int J Oral Maxillofac Surg* 1999;28:95-98.
- Basdra EK, Stellzig A, Komposch G. Functional treatment of condylar fractures in adult patients. *Am J Orthod Dentofacial Orthop* 1998;113:641-646.
- Choi BH, Yi CK, Yoo JH. MRI examination of the TMJ after surgical treatment of condylar fractures. *Int J Oral Maxillofac Surg* 2001;30:296-299.
- De-Riu G, Gamba U, Anghinoni M, Sesenna E. A comparison of open and closed treatment of condylar fractures: A change in philosophy. *Int J Oral Maxillofac Surg* 2001;30:384-389.
- Takenoshita Y, Ishibashi H, Oka M. Comparison of functional recovery after nonsurgical and surgical treatment of condylar fractures. *J Oral Maxillofac Surgery* 1990;48:1191-1195.
- Dahlstrom L, Kahnberg KE, Lindahl L. 15-year follow-up on condylar fractures. *Int J Oral Maxillofac Surg* 1989;18:8-23.
- Lindahl L, Hollender I. Condylar fractures of the mandible. II. A radiographic study of remodeling processes in the temporomandibular joint. *Int J Oral Surg* 1977;6:12-21.
- Sahm G, Witt E. Long-term results after childhood condylar fractures. A computer-tomographic study. *Eur J Orthod* 1989;11:154-160.
- Kahl-Nieke B, Fischbach R, Gerlach KL. CT analysis of temporomandibular joint state in children 5 years after functional treatment of condylar fractures. *Int J Oral Maxillofac Surg* 1994;23:332-337.
- Kahl B, Fischbach R, Gerlach KL. Temporomandibular joint morphology in children after treatment of condylar fractures with functional appliance therapy: A follow-up study using computed tomography. *Dentomaxillofac Radiol* 1995;24:37-45.
- Norholt SE, Krishnan V, Sindet-Pedersen S, Jensen I. Pediatric condylar fractures: A long-term follow-up study of 55 patients. *J Oral Maxillofac Surgery* 1993;51:1302-1310.
- Sekine J, Sano K, Inokuchi T. Effect of aging on rat condylar fracture model evaluated by bromodeoxyuridine immunohistochemistry. *J Oral Maxillofac Surgery* 1995;53:1317-1321.